

## 4 Closing Remarks.

The Cleveland Clinic's online monograph, "Hepatitis C Management" notes the following regarding liver biopsy [11].

For all its advantages, liver biopsy has several important disadvantages. Among them are cost, the risk of complications, the need for additional health care resources, patient and physician aversion to the procedure, inadequate specimen size, and the lack of specific findings.

6

NORMAL FONT

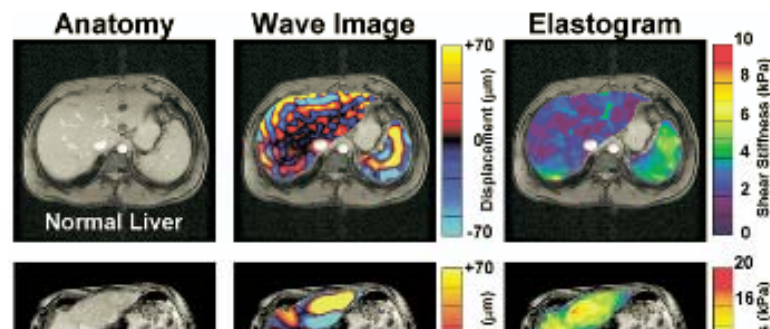
Page 6

BOLD FONT

Page 7

Approximately 20% to 50% of patients will experience significant pain following percutaneous liver biopsy. More severe complications such as pneumothorax, major bleeding, inadvertent biopsy of the kidney or colon, and perforation of the gallbladder have been reported in a fraction of patients (0.57%). There have even been a few reports of death.

Now consider the 2007 MRE-based study by Yin and colleagues which indicates the excellent diagnostic accuracy of assessing hepatic fibrosis non-invasively, cf. Figure 4 [5]. In the case of liver disease, when compared to the potential risk and hardship associated with traditional hepatic biopsy practices the potential of a robust clinical MRE technology to advance the state of the art in world health care is tremendous.



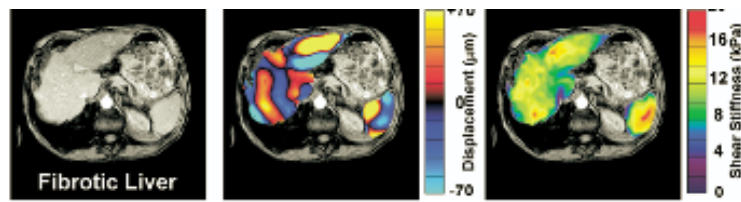


Figure 4: MRE of the liver in a normal volunteer and a patient with cirrhosis. Anatomic images (left), wave images (middle), and elastogram (right). The elastograms show that the mean shear modulus of the fibrotic liver is much higher than that of a normal liver [5].

MRE owes its achievement, in part, to the theory of elasticity. Again, in this case through the development of a revolutionary clinical tool, we see that the efforts of the premier physicists and mathematicians of long ago is still paying dividends to humanity in present day. Perhaps no other words are more befitting than those of the late Professor George Zahalak who once said, “Elasticity is one of the crowing achievements of Western culture!” [10].

## References

- [1] S. A. Kruse, G. H. Rose, K. J. Glaser, A. Manduca, C. J. Felmlee, and R. L. Ehman. Magnetic Resonance Elastography of the Brain. *NeuroImage*, 39:231–237, August 2008.

- [2] S. K. Venkatesh, M. Yin, J. F. Glockner, N. Takahashi, P. A. Araoz, J. A. Talwalkar, and R. L. Ehman. MR Elastography of Liver Tumors: Preliminary Results. *Hepatobiliary Imaging*, 190:1534–1540, June 2008.
- [3] S. A. Kruse, J. A. Smith, A. J. Lawrence, M. A. Dresner, A. Manduca, J. F. Greenleaf, and R. L. Ehman. Tissue Characterization using Magnetic Resonance Elastography: Preliminary Results\*. *Physics in Medicine and Biology*, 45:1579–1590, June 2000.